

Diagnostic Significance of Alpha Feto Protein as a Tumour Marker in Hepatocellular Carcinoma

Narendra Kumar¹, Vibha Sushilendu², Amrendra Kumar³, J.R. Keshri⁴

¹Senior Resident, Dept. of Gastroenterology, ²Senior Resident, Dept of Biochemistry, ³Prof. And Head, Dept of Gastroenterology, ⁴Assoc.Prof., Dept of Biochemistry, IGIMS, Patna

ABSTRACT

Alpha-fetoprotein (α -fetoprotein, AFP) is a large serum glycoprotein, normally produced during fetal development by the liver and yolk sac. AFP may be useful in the diagnosis and follow-up of cases of HCC. Aims and objectives of this study is to estimate and compare the level of AFP in normal subjects and HCC cases and to evaluate the diagnostic significance of AFP as a tumour marker in HCC. AFP level was estimated by CLIA among 44 healthy subjects and 76 HCC cases. 9 out of 44 healthy controls showed increased level of AFP. Among the 76 patients diagnosed with HCC, AFP level was found to be increased in 38 cases. AFP is a significant tumour marker for HCC and can be used as an important tool for assessing the success of treatment regimen and prognosis.

Keywords- AFP –Alpha Feto Protein, HCC-Hepato Cellular Carcinoma, HBV-Hepatitis B Virus, HCV-Hepatitis C Virus.

INTRODUCTION

Alpha-fetoprotein (α -fetoprotein, AFP) is a large serum glycoprotein, belonging to the intriguing class of onco-development protein¹. AFP is normally produced during fetal development by the liver and yolk sac. After birth, the level drops off rapidly, and by the second year only trace amounts are detectable in serum². Although it is most commonly elevated in HCC, elevations in serum AFP can be seen in various malignancies including testicular cancer, bile duct cancer pancreatic cancer, stomach, and colon cancer. Elevated AFP can also be seen with non-malignant conditions including hepatitis and cirrhosis³.

Hepatocellular carcinoma (HCC) is the dominant form of primary liver cancer and is histologically and etiologically distinct from other forms of primary liver cancer⁴. Approximately 70%–90% of patients with HCC have an established background of chronic liver disease and cirrhosis, with major risk factors for developing

cirrhosis including chronic infection with hepatitis B virus (HBV), hepatitis C virus (HCV), alcoholic liver disease, and nonalcoholic steatohepatitis (NASH). Additional risk factors for developing HCC include intake of aflatoxin-contaminated food, diabetes, obesity, certain hereditary conditions such as hemochromatosis, and some metabolic disorders^{5,6,7}.

HCC is unusual among human cancers in that the causative agent is often clear. However, there are multiple etiological factors affecting HCC, all of which vary by geographic location, have a direct impact on the characteristics of these patients, and influence the disease course, making HCC an extremely complex condition associated with a poor prognosis⁸.

AFP may be useful in the diagnosis and follow-up of cases of HCC. It has been suggested that the AFP values are more likely to be elevated with the stage of such cancers and are of prognostic value to check the efficacy of treatment of HCC. Levels of serum AFP are widely used for HCC screening in patients with chronic liver disease (CLD)². Due to the imperative significance of AFP as a tumour marker in HCC, the present study was undertaken in a selected group of patients suffering from hepatic clinical conditions to evaluate AFP levels in patients suspected of hepatocellular carcinoma and to

Corresponding author:

Dr Vibha Sushilendu,

Senior Resident, Dept of Biochemistry, IGIMS, Patna,

Email id: vibhasushilendu@gmail.com

establish a possible correlation with occurrence, cause and extent of the disease.

MATERIAL AND METHOD

The study was conducted in the department of Gastroenterology, IGIMS, Patna over a period of six months. Institutional ethical clearance was taken for this study. A brief history of Patients were taken with clinical symptoms and signs and initial diagnosis. Patients admitted in wards or visiting OPDs with diagnosis or suspicions of HCC due to conditions of Chronic Liver disease (CLDs), hepatitis C (HCV) and hepatitis B viral (HBV) infections, were selected. Subjects with other GI tumours, chronic liver disease without HCC or any other benign liver disorders were excluded from the study. Written consents were taken from all the subjects enrolled for the study.

AFP estimation was done using Chemi Luminescence Immuno Assay method on Beckman Coulter Access 2 machine in the department of Biochemistry IGIMS, Patna. 2ml of venous blood was taken and serum was analysed for AFP.

AFP level >9ng/ml were considered positive.

Data were expressed as mean and SD. MS Excel and SPSS softwares were used for data analysis. A p-value of <0.05 was considered statistically significant.

RESULTS

Out of 44 control subjects taken for, 38 were male and 6 were females with AFP level 7.55 ± 6.3 ng/ml and 7.21 ± 5.9 ng/ml respectively. AFP level was found to be elevated in 18% male and 16% female controls. 76 cases diagnosed with HCC were taken for study of which 69 were males and 7 were females. AFP level in HCC diagnosed cases were 376 ± 94.2 ng/ml in males and 341.16 ± 85.4 ng/ml in females. AFP level was elevated in 38 HCC diagnosed cases with 50% sensitivity and 81% specificity. The highest level of AFP recorded was found to be 3000ng/ml. Among the HCC diagnosed cases, 31 were HBV positive and 3 were infected with HCV, thus making viral infection an important cause of hepatic carcinoma.

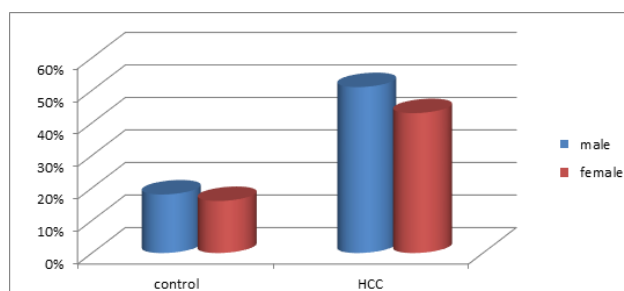


Fig 1. . AFP positivity profile in control and HCC cases

Table 1. Comparative study of AFP level in control and HCC cases

	Control (ng/ml)	HCC (ng/ml)	p value
male	7.55 ± 6.3	376 ± 94.2	<0.01
female	7.21 ± 5.9	341.16 ± 85.41	

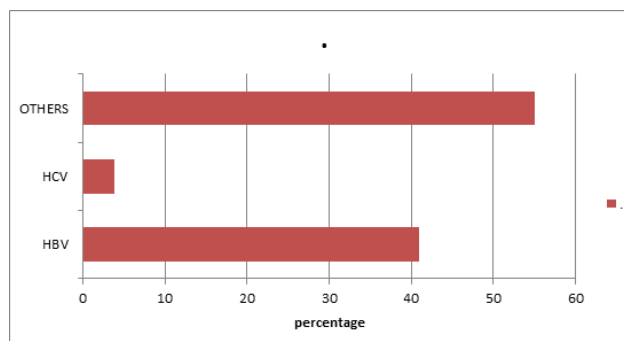


Fig 2. Etiological profile in HCC cases

DISCUSSION

It is well documented that AFP estimation remains a useful test for clinicians, oncologists and physicians involved in the management of patients with foetal defects (spina bifida), hepatic malignancies (HCC, hepatoma, Hepatoblastoma,

Hb), hepatic infections (HCV, HBV) and cancers of pancreas and germ cell^{9,10,11,12}. Favorable outcomes in HCC are more likely when detected at an early stage. Thus, effective screening aims at detecting preclinical HCC. For this purpose, various combinations of AFP testing, imaging with US, CT and/or MRI, are recommended. The role of chronic viral hepatitis in hepatocarcinogenesis is established. Screening patients with chronic viral hepatitis has been shown to result in earlier HCC detection, and reduced cancer mortality. Guidelines for screening and diagnosing HCC by the

American Association for the Study of Liver Diseases (AASLD), and the European Association for the Study of the Liver (EASL), are largely based on studies involving viral-related HCC^{13,14,15}.

Blood AFP level is also used in monitoring response to therapy. Studies on AFP levels in patients with HCC and other benign and malignant liver diseases have shown that serum AFP is greater than 400 ng/ml in 69% of patients with hepatoma. In none of 66 cases of cancer other than HCC was the AFP level greater than 400 ng/ml. In 211 patients with non-malignant liver disease, an AFP level greater than 400 ng/ml was seen in only one patient, a person with chronic aggressive hepatitis. These data suggest that in patients thought to have

HCC on clinical grounds, AFP levels about 400 ng/ml should strongly confirm the presence of HCC by a tissue diagnosis. However, clinicians should remember that some patients with primary hepatic cancer will have normal AFP levels, and normal or moderately elevated levels should not be used to exclude the diagnosis of HCC².

In the present study, AFP positivity was analyzed to check the utility of this marker in HCC and to define the normal AFP levels in matched control groups. A major limitation is the smaller sample size to assess the AFP levels in this group. AFP level was found to be raised in 50% of the HCC cases, while highest level recorded of AFP was 3000 ng/ml.

In a study by Kapoor D, the AFP levels were raised in 65% of the HCC cases, the highest level recorded being 580 ng/ml. Panchanadam M et al found elevated AFP levels in 47.4% of the cases^{16,17}. In yet another study, a positivity of 45.4% was observed among HCC cases. The highest AFP level detected in HCC cases was 739 ng/ml¹⁸.

Previous studies have found that elevated AFP levels are associated with higher pathological grade, more advanced Barcelona Clinic Liver Cancer stage, TNM stage, and larger tumors. Pathological grade, TNM-7 stage, and tumor size are independent risk factors for survival, suggesting that patients with HCC with AFP-positive experience relatively poor survival¹⁹⁻²⁴. These findings were in concordance to the present study.

Studies have shown that AFP, AFP-L3, and des-g-carboxyprothrombin (DCP) are the most useful serum

tumor markers for the detection of HCC, and their simultaneous determination could improve the accuracy, especially in differentiating HCC from non-malignant hepatopathy²⁴⁻²⁹.

CONCLUSION

In conclusion, AFP is a significant marker for Hepatocellular Carcinoma (HCC). It is also helpful in assessing problems in management of HCC and monitoring treatment regimens. Related studies also suggest that AFP is also useful in evaluating malignancies in germ cells and other GI tumours.

Ethical Clearance: Institutional ethical committee, IGIMS, Patna.

Source of Funding: Self

Conflict of Interest: None

REFERENCES

- Gillespie JR, Uversky VN. Structure and function of alpha-fetoprotein: a biophysical overview. *Biochim Biophys Acta* 2000;1480(1-2):41-56.
- Chen DS, Sung JL. Hepatitis B virus infection in Taiwan. *N Engl J Med* 1977;297:668-9.
- Di Bisceglie, A.M., Sterling, R.K., Chung, R.T., Everhart, J.E., Dienstag, J.L., Bonkovsky, H.L., Wright, E.C., Ever-son, G.T., Lindsay, K.L., Lok, A.S., Lee, W.M., Morgan, T.R., Ghany, M.G. and Gretch, D.R. (2005) Serum alpha-fetoprotein levels in patients with advanced hepatitis C: Results from the HALT-C Trial. *Journal of Hepatology*, Di Bisceglie, A.M., Sterling, R.K., Chung, R.T., Everhart, J.E., Dienstag, J.L., Bonkovsky, H.L., Wright, E.C., Ever-son, 43, 434-441.
- Yu MC, Yuan JM, Lu SC. Alcohol, cofactors and the genetics of hepatocellular carcinoma. *J Gastroenterol Hepatol* 2008;23(suppl 1):S92-S97.
- El-Serag HB, Rudolph KL. Hepatocellular carcinoma: Epidemiology and molecular carcinogenesis. *Gastroenterology* 2007;132:2557-2576.
- Montalto G, Cervello M, Giannitrapani L et al. Epidemiology, risk factors, and natural history of hepatocellular carcinoma. *Ann N Y Acad Sci* 2002;963:13-20.
- Gomaa AI, Khan SA, Toledano MB et al.

- Hepatocellular carcinoma: Epidemiology, risk factors and pathogenesis. *World J Gastroenterol* 2008;14:4300–4308.
8. Venook AP, Papandreou C, Furuse J et al. The incidence and epidemiology of hepatocellular carcinoma: A global and regional perspective. *The Oncologist* 2010;15(suppl 4):5–13.
 9. Abelev GI, Lazarevich NL. Alpha-fetoprotein (AFP): solved and unsolved problems. *McGill J Med* 1996;2:127–34.
 10. Bolondi L, Sofia S, Siringo S, Gaiani S, Casali A, Zironi G, Piscaglia F, et al. Surveillance program of cirrhotic patients for early diagnosis and treatment of hepatocellular carcinoma: a cost effectiveness analysis. *Gut* 2001;48:251–9.
 11. Cedrone A, Covino M, Caturelli E, Pompilli M, Lorenzelli G, Villani MR, et al. Utility of alpha-fetoprotein (AFP) in the screening of patients with virus-related chronic liver disease: does different viral etiology influence AFP levels in HCC? A study in 350 western patients. *Hepatogastroenterology* 2000;47:1654–8.
 12. Johnson PJ. The role serum alpha-fetoprotein estimation in the diagnosis and management of hepatocellular carcinoma. *Clin Liver Dis* 2001;5(1):145–59.
 13. Bruix, J. and Sherman, M. (2005) Management of hepatocellular carcinoma: An update. *Hepatology*, 42, 1208- 1236.
 14. Bruix, J., Sherman, M., Llovet, J.M., Beaugrand, M., Lencioni, R., Burroughs, A.K., Christensen, E., Pagliaro, L., Colombo, M. and Rodés J. (2001) Clinical management of hepatocellular carcinoma. Conclusions of the Barcelona 2000 EASL conference. European Association for the Study of the Liver. *Journal of Hepatology*, 35, 421-430.
 15. Bruix, J. and Sherman, M. (2011) Management of hepatocellular carcinoma: An update. *Hepatology*, 53, 1020- 1022.
 16. Kapoor D, Aggarwal SR, Singh NP, Thakur V, Sarin SK. Granulocyte-macrophage colony-stimulating factor enhances the efficacy of hepatitis B virus vaccine in previously unvaccinated haemodialysis patients. *J Viral Hepatol* 1999;6:405–9.
 17. Panchanadam M, Madanagopalan N, Thyagarajan SP, Hill PG, Arumugam S. Correlated clinical, histopathological, HBV and AFP studies of primary carcinoma liver. *Ann Acad Med Singapore*, 1980;9:210–4.
 18. Kailapuri G. Murugavel, et al Alpha-fetoprotein as a tumor marker in hepatocellular carcinoma: investigations in south Indian subjects with hepatotropic virus and aflatoxin Etiologies, *International Journal of Infectious Diseases* (2008) 12, e71–e7
 19. Sauzay, C. et al. Alpha-fetoprotein (AFP): A multi-purpose marker in hepatocellular carcinoma. *Clin Chim Acta.* 463, 39–44(2016).
 20. Blank, S. et al. Assessing prognostic significance of preoperative alpha-fetoprotein in hepatitis B-associated hepatocellular carcinoma: normal is not the new normal. *Ann Surg Oncol.* 21, 986–994 (2014).
 21. An, S. L. et al. Prognostic Significance of Preoperative Serum Alpha-fetoprotein in Hepatocellular Carcinoma and Correlation with Clinicopathological Factors: a Single-center Experience from China. *Asian Pac J Cancer Prev.* 16, 4421–4427 (2015).
 22. Yang, S. L. et al. Distinguished prognosis after hepatectomy of HBV-related hepatocellular carcinoma with or without cirrhosis: a long-term follow-up analysis. *J Gastroenterol.* 51, 722–732 (2016).
 23. Matsumoto, T. et al. Clinical Impact of Anatomical Liver Resection for Hepatocellular Carcinoma with Pathologically Proven Portal Vein Invasion. *World J Surg.* 40, 402–411 (2016).
 24. Xiao, J. et al. Prognostic factors of hepatocellular carcinoma patients treated by transarterial chemoembolization. *Int J Clin Exp Pathol.* 7, 1114–1123 (2014)
 25. Suzuki M, Shiraha H, Fujikawa T, Takaoka N, Ueda N, Nakanishi Y, et al. Des-gamma carboxy prothrombin is a potential autologous growth factor for hepatocellular carcinoma. *J Biol Chem*, 2005;280:6409–15.
 26. Capurro M, Wanless IR, Sherman M, Deboer G, Shi W, Miyoshi E, et al. Glypican-3: a novel serum and histochemical marker for hepatocellular carcinoma. *Gastroenterology* 2003;125:89–97.
 27. Khien VV, Mao HV, Chinh TT, Ha PT, Bang

- MH, Lac BV, et al. Clinical evaluation of lentil lectin-reactive alpha-fetoprotein-L3 in histology-proven hepatocellular carcinoma. *Int J Biol Markers*,2001;16:105—11.
28. Oka H, Saito A, Ito K, Kumada T, Satomura S, Kasugai H, et al.,Multicenter prospective analysis of newly diagnosed hepatocellular carcinoma with respect to the percentage of Lens culinaris agglutinin-reactive alpha-fetoprotein. *J Gastroenterol Hepatol*,2001;16:1378—83.
29. Yamashiki N, Seki T, Wakabayashi M, Nakagawa T, Imamura M, Tamai T, et al. Usefulness of Lens culinaris agglutinin A-reactive fraction of alpha-fetoprotein (AFP-L3) as a marker of distant metastasis from hepatocellular carcinoma. *Oncol Rep* 1999;6:1229—32.