

# Acute Bilateral Diaphragmatic Palsy :Unusual Cause of Orthopnea

Upadhyay Sushil<sup>1</sup>, Lakhnupal Mahima<sup>2</sup>

<sup>1</sup>Senior Consultant Respiratory Medicine, Holy Family Hospital, Delhi, India, <sup>2</sup>Assistant Professor Anaesthesia and Critical Care, Santosh Medical college and hospital Ghaziabad, UP, India

## Abstract

A middle aged lady presented with acute onset respiratory insufficiency without any predisposing factors. Pulmonary, cardiac, neurological and infectious causes were excluded after detailed examination. Bilateral diaphragmatic palsy was considered after meticulous survey. She benefited with non invasive bilevel positive airway pressure (BiPAP) support. High degree of clinical suspicion is stressed in diagnosing bilateral diaphragmatic palsy and excellent results on treatment with non invasive ventilation.

**Keywords:** Bilateral diaphragmatic palsy (BDP), orthopnoea, paradoxical respiration, Non invasive ventilation, Respiratory failure

## Introduction

Acute onset breathlessness is a common clinical emergency. Shortness of breath only in lying down position is defined as orthopnea and can be a presentation of congestive heart failure, acute severe asthma, acute exacerbation of chronic obstructive pulmonary disease or obstructive sleep apnoea. However, after excluding these causes there remains an uncommon etiology which is not usually considered in acute settings and that is bilateral diaphragmatic palsy. It is all the more difficult to figure out when there is no discernible predisposing factor.

Bilateral diaphragmatic paralysis (BDP) is a rare disorder. It can be secondary to spinal cord injury<sup>1</sup>, motor neuron disease, myopathy<sup>2</sup>, non-infectious polyneuropathy, infection<sup>3</sup> or iced saline cardioplegia performed during cardiac surgery<sup>4</sup>. Cause of diaphragmatic palsy, however remains undetermined in almost two-third of cases<sup>5</sup>

The symptoms of diaphragmatic paralysis depend on whether it is unilateral or bilateral, how rapidly it develops, and the presence of underlying pulmonary

disease<sup>6</sup>

Patients with unilateral diaphragmatic paralysis are usually asymptomatic and may spontaneously recover with compensatory mechanisms, especially if there is no underlying pulmonary or neurological disease<sup>7</sup>. It is easily suspected on chest x-ray and can be confirmed with fluoroscopy.

On the other hand, bilateral diaphragmatic paralysis is symptomatic but is difficult to suspect on routine chest x-ray and often missed on fluoroscopy. It is usually a diagnosis of exclusion and needs extended cache of investigations for confirmation<sup>8</sup>.

Bilateral diaphragmatic palsy responds well to non invasive BiPAP application which relieves symptoms and curtails the hospital stay of the patient.

A case of middle age female is presented who developed shortness of breath only seven days before her visit to emergency department. She experienced difficulty typically when lying down on bed and was relieved by sitting up or standing. After excluding cardiac, pulmonary and neuromuscular causes, diagnosis of bilateral diaphragmatic palsy was arrived at after a meticulous survey. Patient got relieved with use of non invasive ventilation and could be sent home on BiPAP support.

---

## Corresponding Author:

**Dr Sushil Upadhyay,**

Senior Consultant Respiratory Medicine, Holy Family Hospital, Delhi, India. Mob: 9899393006

## Case Report

Fifty two year old lady was brought to emergency department with complaint of breathlessness. Her symptom begun one week back when she felt difficulty in lying down because of air hunger. This was not associated with chest pain or choking spells. She denied history of bronchial asthma, chronic obstructive pulmonary disease, coronary heart disease or obstructive sleep apnoea. She has been maintaining elevated upper torso with help of multiple pillows for sleeping since onset of her symptoms.

On examination she appeared little anxious but breathing comfortably in sitting posture and maintaining oxygen saturation of 96% on ambient air. However she resisted lying down on bed. She was admitted for observation and further evaluation under monitored care in high dependency unit. The complete blood counts, liver and renal biochemistries were normal. N terminal beta natriuretic peptide (NT Pro BNP), Troponin-T and Troponin-I were negative. Electrocardiogram showed normal sinus rhythm. Cardiac function as assessed by echocardiography was normal. Chest Xray [Fig 1] showed band like opacities at bases on both sides. Serial arterial blood gas study revealed slight rise in PaCO<sub>2</sub> (48mmHg—52mmHg) [Table 1].

Her lying down position was invariably eventful. Whenever she was asked to lie supine on bed under

supervision she started panting for breath after few seconds and could not maintain it even for a minute. Not only this, her oxygen saturation gradually dropped down till 86% from baseline of 96% in less than a minute. As soon as head end was raised, all her symptoms vanished except for some stress visible on her face. There were no noisy sounds associated with breathlessness.

She had history of low back pain for which MRI was done a year back and it was consistent with lumbar spondylosis. Contrast enhanced computerised tomography (CECT) of thorax revealed basal atelectasis of both lungs without any mediastinal mass or lymphadenopathy. Ultrasound of abdomen showed no subphrenic abnormality. Comprehensive pulmonary function study was conducted [Table 2]. Forced vital capacity was reduced (51%) and so was the maximum inspiratory pressure (25% of the predicted). Sniff PDI was 16cmH<sub>2</sub>O and twitch PDI was 20cm H<sub>2</sub>O. She was referred to neurologist and her electrophysiological study was normal.

Based on above observation and investigations diagnosis was narrowed down to bilateral diaphragmatic palsy. She was put on BiPAP support in lying down position which she accepted well. Her breathing was without any distress and she maintained normal oxygen saturation.

**Table 1. Arterial blood gases:**

pH	Pa CO <sub>2</sub>	PO <sub>2</sub>	HCO <sub>3</sub>	Dated
7.40	48	72	29	13/10/17
7.42	52	47	32	15/10/17

**Table 2. Pulmonary function study:**

parameter	Predicted	Measured	% predicted
FVC	3.04	1.54	51%
FEV1	2.60	1.28	49%
FEV1/FVC%	79%	83%	
RV			116%
TLC			70%
RV/TLC%			158%
DLCO corrected	7.87 ml/min/mmHg	26.22 ml/min/mmHg	30%
MIP	62 cm H <sub>2</sub> O (LLN:50.1)	16cm H <sub>2</sub> O	25%
MEP	82 Cm H <sub>2</sub> O (LLN 66.1)	29cm H <sub>2</sub> O	35%

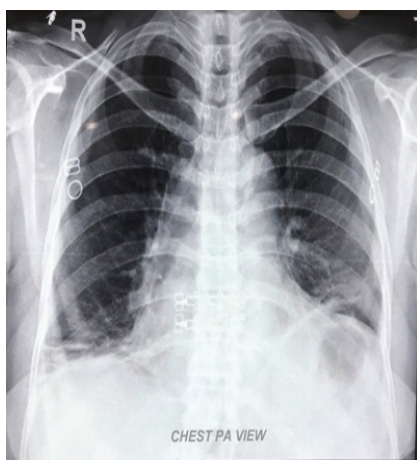


Fig.1: Chest X-ray PA view

## Discussion

The patient presented with breathlessness for less than a week. She was unable to lie down flat on bed and even slept with upper part of body elevated with the help of pillows. She was evaluated for the causes of orthopnea. Cardiopulmonary and neuromuscular causes were ruled out. She was noted to develop panting for breath whenever made to lie down and it was associated with decrease in the oxygen saturation. Thoraco abdominal paradoxical movement was noted during inspiration in supine position which she was unable to sustain more than a minute. Her symptoms resolved on regaining erect position with normalization of oxygen saturation (spO<sub>2</sub>). These episodes were documented multiple times and then bilateral diaphragmatic palsy was considered as possible diagnosis. Non invasive ventilation was applied in lying down position which she tolerated well and oxygen saturation was also well maintained.

Among neuromuscular diseases and conditions, bilateral diaphragmatic paralysis (BDP) has been recognised as a cause of respiratory failure since the decline of poliomyelitis and diphtheritic polyneuropathy<sup>10</sup>.

For a patient with BDP, chest radiography commonly shows elevation of both sides of the diaphragm with volume loss and/or atelectasis at the lung bases<sup>6</sup>. In most cases, severe bilateral diaphragmatic weakness can be diagnosed from physical examination. Chest examination usually reveals limited excursion of the diaphragm, bilateral dullness on percussion over the lower chest and absent breath sounds. The patient may be seen to use accessory muscles, have thoracoabdominal paradoxical respiration, and dyspnea and tachypnea at rest. The symptoms can worsen in the supine position and may

be misinterpreted as a sign of heart failure<sup>11</sup>. There is orthopnea disproportionate to the severity of underlying cardiopulmonary disease.

To suspect diaphragmatic weakness as cause of respiratory insufficiency is challenging and diagnosis is often delayed. This is especially so in cases without any predisposing factors. The median delay in diagnosing BDP is reported to be 2 years with a range of 6 weeks to 10 years<sup>12</sup>.

Unilateral phrenic neuropathies are typically asymptomatic but easily revealed on chest skiagram or fluoroscopy. Bilateral diaphragmatic weakness is always associated with postural breathlessness (orthopnea) but chest xray is insensitive and can be misinterpreted as 'poor inspiratory effort'. Sniff test with fluoroscopy is an aid to diagnose diaphragmatic weakness. There is paradoxical elevation of paralysed diaphragm after vigorous short lived inspiration. This is diagnostic in unilateral diaphragmatic weakness but is most often inconclusive in BDP. In the upright position, active contraction of the abdominal muscles causes upward displacement of the paralysed diaphragm, which is followed by an abrupt termination of abdominal muscular activity in early inspiration, leading to a passive descent of the diaphragm. This passive descent may be mis interpreted during fluoroscopy as evidence of active diaphragmatic contraction<sup>[2,13]</sup>.

Nerve conduction velocity (NCV) and electromyography (EMG) is helpful in demonstrating neuropathic and myopathic function of diaphragm. Absence of twitch on phrenic nerve stimulation in NCV is suggestive of palsy subject to precise localization of the phrenic nerve<sup>13</sup>.

Measurement of transdiaphragmatic pressure with transducer during sniff manuvre is another method of quantitative assessment of diaphragmatic movements and helpful in diagnosis of BDP<sup>13</sup>

Patients with BDP usually present with a restrictive pulmonary disorder, and have marked reduction in functional residual capacity and residual volume because of decreased lung compliance secondary to atelectasis<sup>9</sup>.

In cases where sniff test is negative and clinical suspicion is high, transdiaphragmatic pressure (P<sub>di</sub>) should be measured and is considered the criterion standard for diagnosis. This is done by inserting two thin walled balloons trnasnasally one in the esohagus and the

other in the stomach. During inspiration the esophageal balloon which represents pleural pressure is negative and gastric balloon representing abdominal records positive pressure<sup>15</sup>. There is increase in gradient during normal inspiration. Normal Pdi is 148cmH<sub>2</sub>O in men and 122cmH<sub>2</sub>O in women. In unilateral diaphragmatic palsy maximum Pdi is around 70cmH<sub>2</sub>O and has effect only in forceful manoeuvres like cough and sneeze whereas in bilateral diaphragmatic paralysis it is as low as 40cmH<sub>2</sub>O and can impair normal ventilatory behaviours<sup>16</sup>.

Pulmonary function test unveils decrease in vital capacity (<50% of predicted vital capacity in the upright position and a further reduction of ≥25% in the supine position), and a marked reduction in maximal respiratory pressure[6]. Maximum inspiratory pressure is an indicator of global inspiratory muscle strength but gives significant idea of diaphragmatic weakness if it is significantly low. It is also helpful in monitoring the progress in follow up<sup>14</sup>.

Earlier, tracheostomy used to be the only method to apply positive pressure ventilation for as long as recovery of the condition. Negative pressure ventilation with cuirass or pneumobelt was another modality used in the era of poliomyelitis<sup>12</sup>. However, since the advent non invasive ventilators which can be applied through nasal or oronasal mask, the management of diaphragmatic palsy has taken a dramatic change. On one hand, it has become extremely patient friendly and on the other end by curtailing the prolonged hospital stay it has become practically a domiciliary treatment.

### Conclusion

Bilateral diaphragmatic palsy is an unusual cause of orthopnoea. The diagnosis is arrived at after excluding relatively common etiologies and needs meticulous survey and investigations. Introduction of non invasive ventilation has dramatically changed the management from in-hospital treatment to domiciliary care.

**Conflict of Interest:** Nil

**Source of Funding:** Self

**Ethical Clearance:** NA

### References

1. Glenn WWL, Hogan JF, Loke JSO, Ciesielski TE, Phelps ML, Rowedder R. Ventilatory support by pacing of conditioned diaphragm in quadriplegia. *N Engl J Med* 1984; 310: 1150–1155.
2. Newsom-Davis J. Diaphragm and neuromuscular disease. *Am Rev Respir Dis* 1979; 119 (2):115–117.
3. Dutt AK. Diaphragmatic paralysis caused by herpes zoster. *Am Rev Respir Dis* 1970; 101: 755–758.
4. Kohorst WR, Schonfeld SA, Altman M. Bilateral diaphragmatic paralysis following topical cardiac hypothermia. *Chest* 1984; 85: 65–68.
5. Baum GL, Crapo JD, Celli BR, Karlinsky JB. *Pulmonary diseases*, 6th edn. Philadelphia, PA: Lippincott-Raven, 1998: 1185–8.
6. Fishman AP, Elias JA. *Fishman's Pulmonary Diseases and Disorders*. 4th ed. New York: McGraw-Hill Medical; 2008.
7. Qureshi A. Diaphragm paralysis. *Sem Resp Crit Care Med* 2009; 30:315–320.
8. Billings ME, Aitken ML, Benditt JO (2008) Bilateral diaphragm paralysis: a challenging diagnosis. *Respir Care* 53:1368–1371
9. Laghi F, Jubran A, Topeli A, et al. Effect of lung volume reduction surgery on neuromechanical coupling of the diaphragm. *Am J Respir Crit Care Med* 1998; 157:475–483
10. Luce JM, Huseby JS, Marini JJ. Bilateral diaphragmatic paralysis as a cause of respiratory failure. *West J Med* 1980;132:456–60.
11. Hatakeyama S, Suzuki J, Murakami T, et al. Respiratory failure due to diaphragmatic dysfunction in Charcot-Marie-Tooth disease: a case report. *Nihon Kokyuki Gakkai Zasshi* 2000; 38:637–641.
12. Chan CK, Loke J, Virgulto JA, Mohsenin V, Ferranti, Lammertse T. Bilateral diaphragmatic paralysis: clinical spectrum, prognosis and diagnostic approach. *Arch Phys Med Rehabil* 1988; 69: 976–979.
13. Loh L, Goldman M, Newsom Davis J. Assessment of diaphragm function. *Medicine* 1977;56:165–169.
14. Rochester DF, Arora NS. Respiratory muscle failure. *Med Clin North Am* 1983; 67: 573–597.
15. Miller JM, Moxham J, Green M. The maximal sniff in the assessment of diaphragm function in man. *Clin Sci (Lond)*. 1985 Jul. 69 (1):91–6.
16. McCool FD, Tzelepis GE. Dysfunction of the diaphragm. *N Engl J Med*. 2012 Mar 8. 366 (10):932–42.